

The role of the human medial temporal lobe in object recognition and object discrimination

J. S. Holdstock

University of Liverpool, UK

This paper reviews evidence from neuropsychological patient studies relevant to two questions concerning the functions of the medial temporal lobe in humans. The first is whether the hippocampus and the adjacent perirhinal cortex make different contributions to memory. Data are discussed from two patients with adult-onset bilateral hippocampal damage who show a sparing of item recognition relative to recall and certain types of associative recognition. It is argued that these data are consistent with Aggleton and Brown's (1999) proposal that familiarity-based recognition memory is not dependent on the hippocampus but is mediated by the perirhinal cortex and dorso-medial thalamic nucleus. The second question is whether the recognition memory deficit observed in medial temporal lobe amnesia can be explained by a deficit in perceptual processing and representation of objects rather than a deficit in memory per se. The finding that amnesics were impaired at recognizing, after short delays, patterns that they could successfully discriminate suggests that their memory impairment did not result from an object-processing deficit. The possibility remains, however, that the human perirhinal cortex plays a role in object processing, as well as in recognition memory, and data are presented that support this possibility.

The medial temporal lobes are known to play a critical role in declarative memory (memory for facts and events) in humans, but it is currently unresolved whether the hippocampus and the adjacent medial temporal lobe cortices (entorhinal, perirhinal, and parahippocampal cortices) make distinct contributions to memory, and, if so, what these contributions are. Furthermore, recent work with nonhuman primates has suggested that the role of the perirhinal cortex may not be exclusively one of memory. The current paper focuses primarily on two issues: first, whether recognition memory for individual items in humans is dependent on the integrity of the hippocampus or whether it can be mediated by adjacent cortical regions such as the perirhinal cortex; second, whether the object recognition memory deficit observed in amnesics with medial temporal lobe lesions can be explained by

Correspondence should be addressed to Dr J. S. Holdstock, School of Psychology, University of Liverpool, Eleanor Rathbone Building, Bedford Street South, Liverpool, L69 3BX, UK. Email: J.Holdstock@liverpool.ac.uk
I would like to thank Keith A. May and John J. Downes for their comments on an earlier version of this paper.

a deficit in the perceptual processing and representation of objects rather than a deficit in memory per se.

The human medial temporal lobe and recognition memory

The evidence in relation to the first issue from studies of patients with medial temporal lobe lesions has been conflicting. In some patients, selective hippocampal damage has been reported to impair both recall and recognition (Cipolotti et al., 2001; Manns, Hopkins, Reed, Kitchener, & Squire, 2003; Manns & Squire, 1999; Reed & Squire, 1997). These data have been interpreted as supporting the view that the medial temporal lobe functions as a highly integrated memory system in which both recognition and recall are dependent on the hippocampus (Squire & Zola-Morgan, 1991). However, other patients with selective hippocampal damage have been reported to show a sparing of item recognition relative to recall (Henke et al., 1999; Holdstock, Mayes, Gong, Roberts, & Kapur, 2005b; Holdstock, Mayes, Isaac, Gong, & Roberts, 2002a; Holdstock et al., 2002b; Mayes, Holdstock, Isaac, Hunkin, & Roberts, 2002; Vargha-Khadem, Gadian, Watkins, Connelly, van Paesschen, & Mishkin, 1997). This variability between patients remains to be explained but is not considered in detail here. Possible explanations such as reorganization of function, differences in the tests used by different research groups, differences in location and extent of pathology within and outside of the hippocampus, and differences in strategies used by different patients and different control groups have been discussed in detail elsewhere (see Holdstock et al., 2005b; Mayes et al., 2002; Mayes et al., 2004). While accepting that a number of patients with selective structural hippocampal damage have been reported to show a global amnesia, in this paper I summarize the data from two patients we have tested who have shown a relative sparing of item recognition.

Over a number of years we were able to extensively study the memory of patient YR who had adult-onset selective bilateral hippocampal damage. YR's pathology probably resulted from a vascular incident related to the administration of an opiate drug at the age of 48 years, although this could not be confirmed. Detailed volumetric analysis of YR's structural MRI indicated a bilateral reduction in hippocampal volume of approximately 50%. The volumes of other brain regions including frontal, temporal, and parietal lobes, and perirhinal and entorhinal cortices were comparable to the control mean (see Holdstock et al., 2000b; Mayes et al., 2002; Mayes et al., 2004). As shown in Figure 1, YR performed on average only 0.5 standard deviations below the control mean on a total of 43 item recognition tests, whereas her mean performance was over 3.5 standard deviations below the control mean on a battery of 34 recall tests (Mayes et al., 2002). Taking a criterion of impairment of 1.96 standard deviations below the control mean (Type 1 error probability of .05, two-tailed), YR's item recognition was unimpaired. Although her performance was below average, it cannot be considered to be impaired because, assuming the population is normally distributed, more than 30% of the normal population would be expected to perform worse than her. YR's item recognition performance (measured as number of SDs from the control mean) was unaffected by the difficulty of the tasks for the control subjects, indicating that the relative sparing of item recognition was unlikely to simply reflect better performance on easier tasks (Holdstock et al., 2002b; Mayes et al., 2002). Her performance was also unaffected

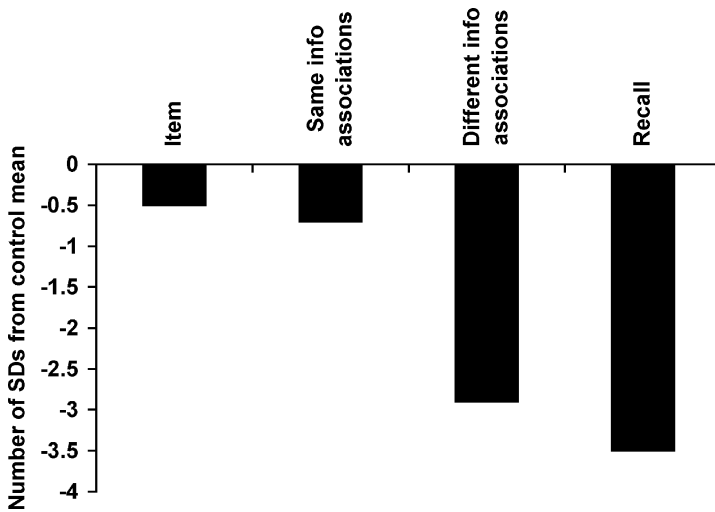


Figure 1. Performance of patient YR, expressed as the number of *SDs* from the mean of matched control subjects, on tests of item recognition, recognition of associations between information of the same kind, recognition of associations between information of different kinds, and recall. Negative values indicate performance below the control mean. *Key:* Item = mean performance on 43 item recognition tests (data from Mayes et al., 2002). Same info associations = mean performance on four tests of recognition of associations between same types of information (e.g., word pairs and face pairs) (data from Mayes et al., 2004). Different info associations = mean performance on 18 tests of recognition of associations between information of different kinds (data from Mayes et al., 2004). Recall = mean performance on 34 recall tests (data from Mayes et al., 2002).

by length of the retention interval, list length, or number of foils (Mayes et al., 2002). YR's performance on forced-choice and yes/no item recognition tests differed only when targets and their corresponding foils were made very similar (Holdstock et al., 2002b; Mayes et al., 2002); under these conditions her yes/no recognition was impaired whereas her forced-choice recognition was unimpaired (Holdstock et al., 2002b). Like item recognition, YR's recognition of word pairs and face pairs was unimpaired. Her mean performance on four tests of this kind was just 0.7 standard deviations below the control mean. In contrast, her mean performance on 18 tests tapping recognition of associations between information of different kinds (e.g., objects and locations, faces and voices, pictures and sounds, new words and their definitions) was 2.9 standard deviations below the control mean and clearly impaired (see Figure 1; Mayes et al., 2004; see also Holdstock et al., 2002a, 2002b; Mayes et al., 2001). This pattern of spared item recognition and recognition of pairs of items of the same kind but impaired recall and recognition of associations between different kinds of information has also been reported for a group of young patients with bilateral hippocampal lesions (Vargha-Khadem et al., 1997). This suggests that some aspects of recognition memory may be spared by hippocampal damage, although this region is critical for recall and also for recognition of associations between different types of information.

A similar, though less striking, dissociation between relatively spared item recognition and impaired recall and associative recognition was observed in another patient, BE, who

also suffered bilateral hippocampal pathology as an adult. BE suffered from herpes simplex encephalitis when he was 45 years old. He was found to have a 37% reduction in right hippocampal volume and a 39% reduction in left hippocampal volume. In contrast, whole temporal lobe volume (which included the hippocampus) was reduced by only 1–2% relative to controls. Although BE's scan was not of sufficient quality for us to estimate the volumes of medial temporal lobe cortices, two independent radiographers who examined the scans considered these regions to be intact. Structural damage therefore appeared to be restricted to the hippocampus bilaterally. However, SPECT and PET scanning revealed that this was accompanied by bilateral hypometabolism in the temporal lobes with SPECT indicating a 25% greater reduction in perfusion in the left than in the right hemisphere (Holdstock et al., 2005b). BE showed deficits of both recognition and recall for verbal material. However, his item recognition for nonverbal material was unimpaired on four of seven forced-choice tests and three of four yes/no tests and above chance on all but one test. In contrast, his recall of nonverbal material and recognition of associations between objects and locations and the temporal order of patterns was impaired and close to chance (Holdstock et al., 2005b). The dissociation between BE's impaired verbal item recognition but relatively spared nonverbal item recognition is unlikely to be explained by his structural damage, as his hippocampus was reduced in volume by a very similar amount on each side (37% vs. 39%). However, it may relate to the difference in severity of hypometabolism in his right and left temporal lobes. Hypometabolism was reported to be less in the right than the left temporal lobe, and, consistent with this, he showed a sparing of nonverbal item recognition relative to recall and associative recognition, but not a similar sparing of verbal item recognition. These data are of considerable interest because, not only do they demonstrate a relative sparing of nonverbal item recognition in this patient, but they also highlight the importance of using functional as well as structural imaging to identify the extent of dysfunction in future case studies. It is possible that the existing conflict in the literature is due, at least in part, to incomplete information about the extent of brain dysfunction in the patients. No functional imaging data have been reported for the majority of patients with selective hippocampal damage including those, reported by Squire and his colleagues (Manns et al., 2003; Manns & Squire, 1999; Reed & Squire, 1997), who have both recall and recognition deficits. It is therefore possible that the patients who have a global amnesia after selective structural hippocampal damage have greater dysfunction outside of the hippocampus, not detected by a structural scan, than those who have a relative sparing of item recognition. The additional information that functional imaging can provide will help to determine whether this is the case.

Although, as discussed above, the reported effects of selective structural hippocampal lesions on memory have been variable, the fact that recognition of items and word and face pairs has been spared by hippocampal damage in at least some patients is consistent with the view that familiarity-based memory decisions are not dependent on the hippocampus but can be supported by neocortical regions (Aggleton & Brown, 1999; Norman & O'Reilly, 2001; see also O'Reilly & Norman, 2002). Electrophysiological studies have shown that neurons in the anterior inferior temporal lobe have the response properties necessary to support familiarity judgements (Brown & Bashir, 2002). Further, lesion studies in monkeys and rats have shown that selective lesions of the perirhinal cortex and dorso-medial nucleus of the thalamus produce deficits in object recognition (Meunier, Bachevalier, Mishkin, & Murray, 1993; Meunier, Hadfield, Bachevalier, & Murray, 1996) whereas object recognition

is, at most, mildly impaired by lesions of the hippocampus (Alvarez, Zola-Morgan, & Squire, 1995; Murray & Mishkin, 1986, 1996; Zola-Morgan & Squire, 1986; Zola-Morgan, Squire, & Amaral, 1989; Zola-Morgan, Squire, Clower, & Rempel, 1993), fornix (Aggleton, Hunt, & Shaw, 1990; Bachevalier, Parkinson, & Mishkin, 1985a; Bachevalier, Saunders, & Mishkin, 1985b; Gaffan, Sheilds, & Harrison, 1984; Rothblat & Kromer, 1991; Shaw & Aggleton, 1993; Zola-Morgan et al., 1989) parahippocampal cortex (Meunier et al., 1996; Ramus, Zola-Morgan, & Squire, 1994) and entorhinal cortex (Leonard, Amaral, Squire, & Zola-Morgan, 1995; Meunier et al., 1993). These findings led Aggleton and Brown (1999) to suggest that familiarity-based recognition decisions may be mediated by a system that includes the perirhinal cortex, dorso-medial thalamic nucleus, and prefrontal cortex, whereas recall/recollection is supported by a system that includes the hippocampus, anterior thalamic nucleus, and prefrontal cortex.

The view of Aggleton and Brown (1999) predicts that, after bilateral hippocampal damage, patients will rely primarily on familiarity when making their memory decisions. Consistent with this proposal, estimates of familiarity obtained from eight tests that used the remember/know procedure indicated that familiarity was probably normal in YR (Holdstock et al., 2002b). Mean estimates of familiarity for YR were above the control mean when assumptions of independence and exclusivity were made and 0.17 standard deviations below the control mean when a redundancy relationship was assumed. It was also shown that YR's discrimination of studied line-drawn pictures from very similar foils was unimpaired when a forced-choice paradigm was used but not when a yes/no paradigm was used (Holdstock et al., 2002b). According to the computational model of Norman and O'Reilly (Norman & O'Reilly, 2001; see also O'Reilly & Norman, 2002), with forced-choice tasks, good performance can be achieved using familiarity alone, whereas with yes/no tasks involving very similar targets and foils, good performance relies on the use of recollection. Using the remember/know procedure with a forced-choice paradigm, we also found that patient BE based his forced-choice item recognition decisions on a feeling of familiarity more often than did control subjects (Holdstock et al., 2005b). The data therefore suggest that the two patients rely primarily on familiarity in making their recognition memory decisions.

Many researchers assume that there is an independence relationship between recollection and familiarity (see Yonelinas, 2002)—that is, the occurrence of recollection does not depend on or influence the occurrence of familiarity or vice versa. This means that, for a healthy individual, any item recognition decision may be based on recollection alone, familiarity alone, or both familiarity and recollection. If the patients can only base their recognition decisions on familiarity, it may not be surprising that, although item recognition has been relatively spared in some patients with hippocampal damage, performance has been below the control mean. This is because, although for both patients and controls there would be occasions when they would be able to use familiarity as a basis for their recognition decisions, for the control subjects there would be additional occasions when familiarity is absent but recollection can be used as a basis for their recognition decisions.

Although data from patients such as YR and BE have suggested that the hippocampus is not necessary for familiarity-based item recognition, alone they have not provided any constraints as to which regions may mediate this type of recognition in humans. Of relevance to this issue, Holdstock, Gutnikov, Gaffan, and Mayes (2000a) compared the pattern recognition performance of a mixed group of patients with anterograde amnesia with that

of patient YR. The amnesic group comprised four patients with extensive medial temporal lobe damage due to either encephalitis or meningitis, two patients who had suffered Wernicke Korsakoff syndrome and so were likely to have damage to both the anterior and dorso-medial thalamic nuclei (although scan information was not available to confirm this), one patient who had suffered from a posterior communicating artery aneurysm, which had resulted in pathology in the posterior temporal lobe, right medial temporal lobe, and occipital cortex, and two patients who had suffered from anterior communicating artery aneurysms. The patients completed a matching-to-sample task for grey-scale computer-generated patterns. Participants viewed a single pattern, which appeared in the centre of the screen for 2.5 s and then disappeared. After delays ranging from 0 to 30 s, 14 patterns appeared on the screen, and the one that was identical to the sample had to be selected. There was also a simultaneous matching condition in which the sample remained on the screen while participants decided which of the choice stimuli matched it. The data from this study are shown in Figure 2. The amnesic group was unimpaired at simultaneous matching and at matching after unfilled delays of 0, 2, and 5 s. However, after filled delays of 10, 20, and 30 s, which are likely to have been tapping long-term memory, the amnesic group was

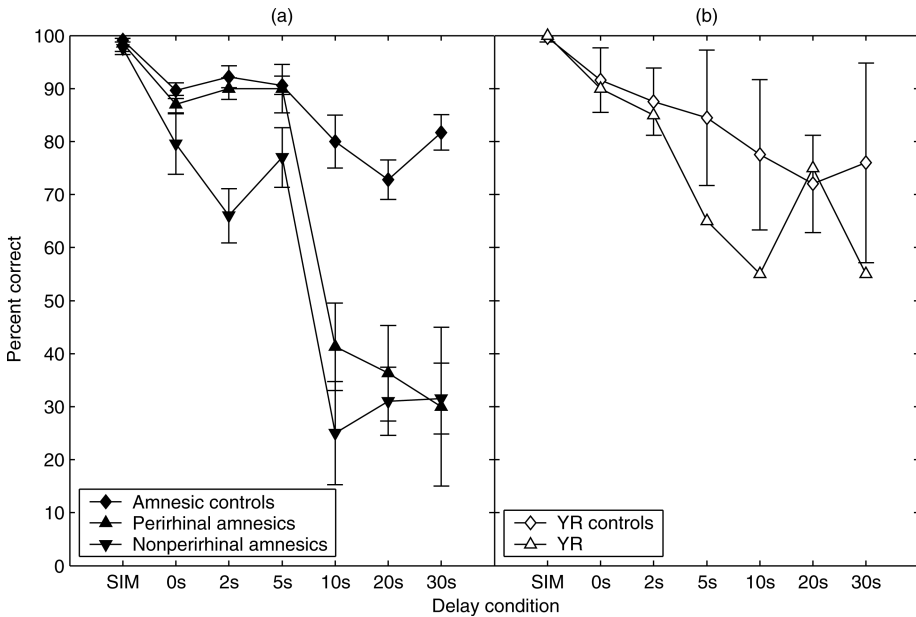


Figure 2. (a) Percentage of correct performance on pattern matching-to-sample of amnesic patients with confirmed damage to the perirhinal cortex (perirhinal amnesics), amnesic patients with no confirmed damage to the perirhinal cortex (nonperirhinal amnesics), and control subjects for the mixed amnesic group (amnesic controls). Error bars indicate the standard error of the mean. (b) Percentage of correct performance on pattern matching-to-sample of patient YR (YR) and YR's matched control group (YR controls). Error bars indicate the standard deviation of the control group. Data replotted from Figure 2 of "Perceptual and mnemonic matching-to-sample in humans: Contributions of the hippocampus, perirhinal and other medial temporal lobe cortices", by J. S. Holdstock, S. A. Gutnikov, D. Gaffan, and P. R. Mayes (2000), *Cortex*, 36, p. 312. Copyright © 2000, Masson S. p. A. Adapted with permission.

significantly impaired relative to its control group. This impairment was evident at the 10-s delay with little further forgetting after this time. When the patient group was subdivided into those with confirmed perirhinal cortex damage and those without confirmed perirhinal cortex damage, the latter group was found to be impaired from delays of 2 s onwards whereas the former was only impaired after a 10-s delay. However, analysis of variance (ANOVA) showed no significant interaction between amnesic subgroup and delay. In contrast to the memory deficits shown by the amnesic group, patient YR's performance was unimpaired (using a criterion of impairment of 1.96 standard deviations below the control mean) and within the range of her matched control group for all delays. Furthermore, YR's performance was over 2 standard deviations better than the mean of the amnesic group at the 20-s delay and over 1 standard deviation better than the amnesic group mean at delays of 10 and 30 s (Holdstock et al., 2000a). YR achieved this good level of performance even though, in all delayed conditions, her response times were between 2 and 10 standard deviations slower than those of the amnesic patients and controls, suggesting that her memory was effectively being tested after longer delays than those for the other participants, which may have led to her percentage correct performance being underestimated (see Holdstock et al., 2000a).

YR's data suggested that damage to the hippocampus was not sufficient to produce a deficit on this task, suggesting that the deficit shown by the mixed amnesic group was most likely to be due to the damage or dysfunction that these patients had suffered outside of the hippocampus. The patients with medial temporal lobe damage all had MRI-confirmed damage to the perirhinal cortex as well as pathology to additional regions in the medial temporal lobe. The patient who had suffered a posterior communicating artery aneurysm also had medial temporal lobe damage, although there was no confirmation of the exact regions involved. Their data are therefore consistent with Aggleton and Brown's (1999) proposal that a circuit involving perirhinal cortex, dorso-medial thalamus, and prefrontal cortex may mediate familiarity-based item recognition. The data from patients who had suffered from Wernicke Korsakoff syndrome are also consistent with this view, as this disease has been associated with damage to the dorso-medial thalamic nucleus as well as the anterior-thalamic nucleus, which forms part of Aggleton and Brown's hippocampal circuit (Harding, Halliday, Caine, & Kril, 2000). Clipping of anterior communicating artery aneurysms is thought to have a disruptive effect on memory by disconnecting the medial temporal lobe and inferior temporal cortex from cholinergic inputs from the basal forebrain, which is damaged in this patient group (Abe, Inokawa, Kashiwagi, & Yanagihara, 1998; Easton, Ridley, Baker, & Gaffan, 2002). These patients are therefore likely to have extensive medial temporal lobe dysfunction affecting both systems proposed by Aggleton and Brown.

Although the data from Holdstock et al. (2000a) are consistent with the Aggleton and Brown (1999) view, given the widespread brain damage suffered by the mixed amnesic group, stronger evidence is needed concerning the specific contribution of the perirhinal cortex and dorso-medial thalamic nucleus to recognition memory in humans, and this requires studies of patients with more selective damage to these regions. One such study (Isaac et al., 1998) reported both recall and recognition memory deficits in a patient with a bilateral lesion to the dorso-medial thalamic nucleus and some slight atrophy to the mammillary bodies bilaterally. This suggested that the effect of damage to the perirhinal cortex-dorso-medial thalamic system may extend to recall as well as recognition in humans. One possible explanation of this could be that familiarity mediated by this system may be

required for normal recall (Isaac et al., 1998). If so, a double dissociation between the effects of hippocampal system damage and perirhinal system damage on recall and item recognition may not be found in humans, although as the input of spatial information into the hippocampal system is thought to be via the parahippocampal cortex rather than the perirhinal cortex, a double dissociation between spatial and item recognition memory may be found (Isaac et al., 1998). The investigation of further cases is required to confirm whether this is the case.

The human medial temporal lobe and object discrimination

The data from Holdstock et al. (2000a) also relate to the second question to be addressed in this paper—that is, whether the recognition memory deficit found in patients with medial temporal lobe amnesia may be attributed to a deficit in object processing and representation rather than a deficit in recognition memory per se. This question has arisen from the findings of studies of nonhuman primates, which have reported object-processing deficits following lesions of the rhinal (perirhinal and entorhinal) or perirhinal cortex (Buckley, this issue; Bussey, Saksida, & Murray, this issue).

The first study to suggest such a deficit showed that monkeys with rhinal lesions were impaired at the simultaneous matching of objects when trial-unique stimuli were used (Eacott, Gaffan, & Murray, 1994). The matching-to-sample task reported by Holdstock et al. (2000a) used stimuli and a task design similar to that used by Eacott et al. Both studies required simultaneous matching and matching after a 0-s delay. Holdstock and colleagues used trial-unique patterns consisting of overlapping complex shapes whereas Eacott et al. used trial-unique patterns composed of overlapping typographical figures. Unlike Eacott and colleagues, we found that the performance of the mixed group of amnesic patients was unimpaired in both the simultaneous and the 0-s delay conditions (see Figure 2). In fact, when the performance of just those patients with MRI-confirmed structural damage to the perirhinal cortex was considered, performance was unimpaired at all delays up to and including the unfilled 5-s delay. Performance was only impaired at the filled delays of 10 s and longer, which are likely to have tapped long-term memory. The patients with medial temporal lobe damage that included damage to the perirhinal cortex were therefore impaired at recognizing abstract patterns after delays of 10 s or longer even though they could accurately discriminate between these stimuli when the task made no demands on memory.

The data from Holdstock et al. (2000a) suggest that the recognition deficit following medial temporal lobe damage in humans is not merely a reflection of a deficit in object processing. However, stronger evidence for this argument would be provided if performance of the participants was not at ceiling in the simultaneous condition. It could be argued that the ceiling effect in the simultaneous condition of Holdstock et al. (2000a) hid an object-processing deficit in the patient group, which only became apparent when the task was made more difficult by making demands on memory. We considered this explanation to be unlikely, but it cannot be excluded until it is demonstrated that patients whose damage includes the perirhinal cortex are unimpaired at simultaneous matching on a task on which performance is below ceiling and yet are impaired at recognition of these kinds of stimuli at longer delays. This is currently being explored with a modified version of the task.

Although the data from Holdstock et al. (2000a) suggest that the recognition deficit following medial temporal lobe damage in humans is unlikely to be attributable to a deficit in object processing, they do not rule out the possibility that the perirhinal cortex plays a role in object processing, in addition to its contribution to recognition memory, but that the discrimination of the stimuli used by Holdstock et al. did not require this process. Although the stimuli were based on those used by Eacott and colleagues (Eacott et al., 1994), humans found the task easier than did the monkeys and were perhaps basing their discriminations on more simple features. This may also have been true of the study reported by Buffalo, Reber, and Squire (1998), which also used trial-unique abstract patterns and found a deficit in yes/no recognition only from delays of 6 s in patients with medial temporal lobe lesions that included perirhinal cortex (see Lee, Barense, & Graham, this issue, for a similar proposal).

The nonhuman primate literature subsequent to the study of Eacott et al. (1994) has suggested that perirhinal cortex lesions impair object processing under some but not all conditions. Impairments have been reported in object discrimination learning when large sets of discriminations were used (Buckley & Gaffan, 1997; although see Hampton & Murray, 2002), large numbers of foils were used (Buckley & Gaffan, 1997), or when the rewarded item was presented in different views on different trials (Buckley & Gaffan, 1998). Deficits were also reported in selecting an odd one out (different object/face) from among different views of a single object (or face) but not from among identical views of a single object (or face; Buckley, Booth, Rolls, & Gaffan, 2001). Impairments were also not seen when detection of the odd one out required fine discriminations of colour, size, or shape (Buckley et al., 2001). It was argued that the tasks on which there were impairments placed high demands on object identification. However, perirhinal cortex damage in monkeys does not impair discrimination under all conditions that increase demands on object identification (Hampton, this issue; Hampton & Murray, 2002).

Bussey and Saksida (2002) have proposed that the key determinant of whether the perirhinal cortex is critical for object identification in a particular task is the extent to which discrimination of objects in that task requires the representation of complex conjunctions of visual features. They argue that the ventral visual processing stream is organized hierarchically so that, although conjunctions of features are represented throughout the ventral visual processing stream, the most complex conjunctions are represented by the perirhinal cortex (Bussey & Saksida, 2002). In support of this model it has been shown that concurrent object discrimination learning was impaired by perirhinal cortex ablations in monkeys when feature ambiguity was high (a photographed scene was rewarded when it was part of one object, but not rewarded when it was part of another object) but that the deficit decreased with decreasing feature ambiguity (Bussey, Saksida, & Murray, 2002, this issue). Further, perirhinal cortex lesions impaired picture discrimination when the stimuli to be discriminated shared a number of features but not when they were perceptually distinct or when difficult colour or shape discriminations were tested (Bright, Moss, Stamatakis, & Tyler, this issue; Bussey, Saksida, & Murray, 2003).

The few studies relevant to this issue in the patient literature have reported conflicting findings. Stark and Squire (2000) found no deficits in three patients with complete bilateral perirhinal cortex damage on tasks modelled on the odd-one-out tasks used by Buckley and colleagues (2001). In contrast, Lee et al. (2005) found deficits in scene and face discrimination and

a possible milder deficit in object discrimination in three patients with medial temporal lobe damage that included perirhinal cortex. The issue of whether the human perirhinal cortex is involved in representing complex conjunctions of visual features of objects is therefore unresolved and awaits further studies to explore the generality of the reported deficits to other patients with perirhinal cortex damage and the systematic investigation of the conditions under which such deficits are found in humans (see Lee et al., this issue).

Given the anatomical position of the perirhinal cortex it is plausible to argue that it may not only be involved in representing complex conjunctions of visual features of objects but that it may also be involved in representing conjunctions of object features from different sensory modalities (Goulet & Murray, 2001; Murray & Bussey, 1999). However, there appears to be little evidence directly related to this issue in the literature. Aspiration lesions of the amygdala, which will have directly or indirectly affected the adjacent entorhinal and perirhinal cortices, have been reported to impair delayed-non-matching-to-sample (DNMS) when the sample object was presented tactually and the choices were presented visually, but not when sample and choice items were both presented in the same modality (visual or tactile; Málková & Murray, 1996; Murray & Mishkin, 1985). The importance of perirhinal cortex damage/dysfunction to the occurrence of this deficit is suggested by the finding that an excitotoxic lesion to the amygdala produced only a transient impairment on crossmodal DNMS, whereas a lesion to the rhinal cortex consistently impaired crossmodal DNMS (Goulet & Murray, 2001). The memory component that forms part of this task, however, makes it difficult to determine whether the deficit is one of crossmodal object processing or one of memory.

Evidence from two studies of patients with damage to the medial temporal lobe suggests that this region may indeed be involved in crossmodal object processing. Shaw, Kentridge, and Aggleton (1990) showed that patients who had suffered from herpes simplex encephalitis, which causes pathology in the medial temporal lobe, were impaired at matching a test arc with a comparison circle when the stimuli were presented in different modalities (visual and tactile) but not when they were presented in the same modality (visual or tactile). Although the authors attributed the deficit to damage to the amygdala, given their aetiology these patients are also likely to have had damage to the perirhinal cortex, although MRI was not available to confirm this.

In recent unpublished work (Holdstock, Blay, Denby, Downes, Roberts, & Mayes, 2005a), crossmodal and intramodal matching were tested in two patients who both had abnormality of the right amygdala and right perirhinal cortex. One patient, a 45-year-old female, JL, had suffered from a head injury at the age of 17 years, and detailed investigation using structural MRI showed that as a result she had damage to medial and lateral orbitofrontal cortex on the right and to bilateral superior, middle, and inferior temporal gyri. Damage to the temporal lobe affected the anterior 60% on the left and the anterior 40% on the right. Volumetric measures showed that the volume of JL's perirhinal cortex was reduced bilaterally but to a greater extent on the right, whereas the volumes of entorhinal cortex and hippocampus were normal bilaterally. She also had partial damage to the right amygdala but volume measures could not be obtained for this structure because of the proximity of the cortical damage (for more detailed information about JL's pathology and neuropsychological test performance see Mayes et al., 2003; and Holdstock et al., 2002a). The second patient, VG, was a 40-year-old male who presented with memory problems but had not suffered from an illness or

injury from which this may have resulted. Volumetric analysis of structural MRI revealed a reduction in volume of more than 2 standard deviations relative to the control mean in right hippocampus, amygdala, and perirhinal cortex and a bilateral reduction in entorhinal cortex volume. The volumes of hippocampus, amygdala and perirhinal cortex on the left and the volumes of the left and right temporal lobes were comparable to control mean volumes. The patients were investigated as two separate case studies, and their test performance was compared with that of age-, sex-, and IQ-matched control groups. Both patients showed an identical pattern of performance. The tasks involved selecting which of a number of choice stimuli (abstract shapes) was identical to a simultaneously presented sample stimulus. The sample and choice stimuli were both presented in the visual modality or both presented in the tactile modality, or the sample was presented in the tactile modality, and the choices were presented visually. Consistent with the findings of Shaw and colleagues (1990), the patients were only impaired in the crossmodal matching condition. These data therefore suggest that the role of the perirhinal cortex in object processing may not be restricted to the representation of complex conjunctions of visual features of objects but that it may also be involved in the integration of information about objects from different modalities. However, the data are based on the performance of only a small number of patients, and to be more confident in this conclusion it will be important to demonstrate a similar pattern in larger numbers of patients with damage to this brain region.

Conclusion

In summary, this paper has reviewed the evidence from neuropsychological patient studies relevant to two questions concerning the functions of the medial temporal lobe in humans.

The first question was whether there is evidence to suggest that the hippocampus and the adjacent perirhinal cortex make different contributions to memory. Although the evidence from patients with hippocampal damage is mixed, and further work is required to identify the reasons for the varying patterns of performance that have been reported, the fact that some patients with adult-onset selective hippocampal damage have shown a sparing of item recognition, relative to recognition of associations between different types of information and to recall, suggests that regions other than the hippocampus may be able to support item recognition performance. Given that patients with more extensive medial temporal lobe lesions are impaired on item recognition tests, this finding is consistent with the proposal of Aggleton and Brown (1999) that the hippocampus forms part of a system that supports recall and recollection, whereas the perirhinal cortex and dorso-medial thalamic nucleus support familiarity-based recognition memory.

The second question is whether the recognition memory deficit seen after medial temporal lobe lesions in humans can be attributed to a deficit in object processing rather than memory per se. The evidence presented from the study of Holdstock et al. (2000a) suggests that any perceptual role of the perirhinal cortex is likely to be separable from its role in recognition memory. Although in that study a deficit in object processing was not obtained, studies using tasks in humans that require discriminations on the basis of more complex conjunctions of visual features or the integration of information from different modalities have produced deficits in patients whose damage includes the perirhinal cortex. These data suggest that the perirhinal cortex may contribute to the processing and representation

of objects in humans in addition to mediating familiarity-based recognition memory, but further studies are required to strengthen the evidence for this conclusion.

REFERENCES

- Abe, K., Inokawa, M., Kashiwagi, A., & Yanagihara, T. (1998). Amnesia after a discrete basal forebrain lesion. *Journal of Neurology, Neurosurgery and Psychiatry*, *65*, 126–130.
- Aggleton, J. P., & Brown, M. (1999). Episodic memory, amnesia and the hippocampal-anterior thalamic axis. *Behavioral Brain Sciences*, *22*, 425–490.
- Aggleton, J. P., Hunt, P. R., & Shaw, C. (1990). The effects of mammillary body and combined amygdala-fornix lesions on tests of delayed non-matching-to-sample in the rat. *Behavioural Brain Research*, *40*, 145–157.
- Alvarez, P., Zola-Morgan, S., & Squire, L. R. (1995). Damage limited to the hippocampal region produces long-lasting memory impairment in monkeys. *Journal of Neuroscience*, *15*, 3796–3807.
- Bachevalier, J., Parkinson, J. K., & Mishkin, M. (1985a). Visual recognition in monkeys: Effects of separate vs. combined transection of fornix and amygdalofugal pathways. *Experimental Brain Research*, *57*, 554–561.
- Bachevalier, J., Saunders, R. C., & Mishkin, M. (1985b). Visual recognition in monkeys: Effects of transection of fornix. *Experimental Brain Research*, *57*, 547–553.
- Bright, P., Moss, H. E., Stamatakis, E. A., & Tyler, L. K. (this issue). The anatomy of object processing: The role of anteromedial temporal cortex. *Quarterly Journal of Experimental Psychology*, *58B*, 361–377.
- Brown, M. W., & Bashir, Z. I. (2002). Evidence concerning how neurons of the perirhinal cortex may effect familiarity discrimination. *Philosophical Transactions of the Royal Society of London B*, *357*, 1083–1095.
- Buckley, M. J. (this issue). The role of the perirhinal cortex and hippocampus in learning, memory and perception. *Quarterly Journal of Experimental Psychology*, *58B*, 246–268.
- Buckley, M. J., Booth, M. C. A., Rolls, E. T., & Gaffan, D. (2001). Selective perceptual impairments after perirhinal cortex ablation. *The Journal of Neuroscience*, *21*, 9824–9836.
- Buckley, M. J., & Gaffan, D. (1997). Impairment of visual object-discrimination learning after perirhinal cortex ablation. *Behavioural Neuroscience*, *111*, 467–475.
- Buckley, M. J., & Gaffan, D. (1998). Perirhinal cortex ablation impairs visual object identification. *The Journal of Neuroscience*, *18*, 2268–2275.
- Buffalo, E. A., Reber, P. J., & Squire, L. R. (1998). The human perirhinal cortex and recognition memory. *Hippocampus*, *8*, 330–339.
- Bussey, T. J., & Saksida, L. M. (2002). The organization of visual object representations: A connectionist model of effects of lesions in perirhinal cortex. *European Journal of Neuroscience*, *15*, 335–364.
- Bussey, T. J., Saksida, L. M., & Murray, E. A. (2002). Perirhinal cortex resolves feature ambiguity in complex visual discriminations. *European Journal of Neuroscience*, *15*, 365–374.
- Bussey, T. J., Saksida, L. M., & Murray, E. A. (2003). Impairments in visual discrimination after perirhinal cortex lesions: testing 'declarative' vs. 'perceptual-mnemonic' views of perirhinal cortex function. *European Journal of Neuroscience*, *17*, 649–660.
- Bussey, T. J., Saksida, L. M., & Murray, E. A. (this issue). The perceptual-mnemonic/feature conjunction model of perirhinal cortex function. *Quarterly Journal of Experimental Psychology*, *58B*, 269–282.
- Cipolotti, L., Shallice, T., Chan, D., Fox, N., Scallan, R., Harrison, G. et al. (2001). Long-term retrograde amnesia... the crucial role of the hippocampus. *Neuropsychologia*, *39*, 151–172.
- Eacott, M. J., Gaffan, D., & Murray, E. A. (1994). Preserved recognition memory for small sets, and impaired stimulus identification for large sets, following rhinal cortex ablations in monkeys. *European Journal of Neuroscience*, *6*, 1466–1478.
- Easton, A., Ridley, R. M., Baker, H. F., & Gaffan, D. (2002). Unilateral lesions of the cholinergic basal forebrain and fornix in one hemisphere and inferior temporal cortex in the opposite hemisphere produce severe learning impairments in rhesus monkeys. *Cerebral Cortex*, *12*, 729–736.
- Gaffan, D., Shields, C., & Harrison, S. (1984). Delayed matching by fornix-transected monkeys: The sample, the push and the bait. *Quarterly Journal of Experimental Psychology*, *36B*, 305–317.
- Goulet, S., & Murray, E. A. (2001). Neural substrates of crossmodal association memory in monkeys: The amygdala versus the anterior rhinal cortex. *Behavioral Neuroscience*, *115*, 271–284.

- Hampton, R. R. (this issue). Monkey perirhinal cortex is critical for visual memory, but not for visual perception: Re-examination of the behavioural evidence from monkeys. *Quarterly Journal of Experimental Psychology*, *58B*, 283–299.
- Hampton, R. R., & Murray, E. A. (2002). Learning of discriminations is impaired, but generalization to altered views is intact, in monkeys (macca mulatta) with perirhinal cortex removal. *Behavioral Neuroscience*, *116*, 363–377.
- Harding, A., Halliday, G., Caine, D., & Kril, J. (2000). Degeneration of anterior thalamic nuclei differentiates alcoholics with amnesia. *Brain*, *123*, 141–154.
- Henke, K., Kroll, N. E. A., Behnia, H., Amaral, D. G., Miller, M. B., Rafal, R. et al. (1999). Memory lost and regained following bilateral hippocampal damage. *Journal of Cognitive Neuroscience*, *11*, 682–697.
- Holdstock, J. S., Blay, K., Downes, J. J., Denby, C., Roberts, N., & Mayes, A. R. (2005a). *Intra-modal and cross-modal matching-to-sample following pathology to the right perirhinal cortex and amygdala in humans*. Manuscript in preparation.
- Holdstock, J. S., Gutnikov, S. A., Gaffan, D., & Mayes, A. R. (2000a). Perceptual and mnemonic matching-to-sample in humans: Contributions of the hippocampus, perirhinal and other medial temporal lobe cortices. *Cortex*, *36*, 301–322.
- Holdstock, J. S., Mayes, A. R., Cezayirli, E., Isaac, C. L., Aggleton, J. P. & Roberts, N. (2000b). A comparison of egocentric and allocentric spatial memory in a patient with selective hippocampal damage. *Neuropsychologia*, *38*, 410–425.
- Holdstock, J. S., Mayes, A. R., Gong, Q. Y., Roberts, N., & Kapur, N. (2005b). Item recognition is less impaired than recall and associative recognition in a patient with selective hippocampal damage. *Hippocampus*, *15*, 203–215.
- Holdstock, J. S., Mayes, A. R., Isaac, C. L., Gong, Q., & Roberts, N. (2002a). Differential involvement of the hippocampus and temporal lobe cortices in rapid and slow learning of new semantic information. *Neuropsychologia*, *40*, 748–768.
- Holdstock, J. S., Mayes, A. R., Roberts, N., Cezayirli, E., Isaac, C. L., O'Reilly, R. et al. (2002b). Under what conditions is recognition spared relative to recall after selective hippocampal damage in humans? *Hippocampus*, *12*, 341–351.
- Isaac, C. L., Holdstock, J. S., Cezayirli, E., Roberts, J. N., Holmes, C. J., & Mayes, A. R. (1998). Amnesia in a patient with lesions limited to the dorsomedial thalamic nucleus. *Neurocase*, *4*, 497–508.
- Lee, A. C. H., Barense, M. D., & Graham, K. S. (this issue). The contribution of the human medial temporal lobe to perception: Bridging the gap between animal and human studies. *Quarterly Journal of Experimental Psychology*, *58B*, 300–325.
- Lee, A. C. H., Bussey, T. J., Murray, E. A., Saksida, L. M., Epstein, R. A., Kapur, N. et al. (2005). Perceptual deficits in amnesia: Challenging the medial temporal lobe 'mnemonic' view. *Neuropsychologia*, *43*, 1–11.
- Leonard, B. W., Amaral, D. G., Squire, L. R., & Zola-Morgan, S. (1995). Transient memory impairment in monkeys with bilateral lesions of the entorhinal cortex. *Journal of Neuroscience*, *15*, 5637–5659.
- Málková, L., & Murray, E. A. (1996). Effects of partial versus complete lesions of the amygdala on cross-modal associations in cynomolgus monkeys. *Psychobiology*, *24*, 255–264.
- Manns, J. R., Hopkins, R. O., Reed, J. M., Kitchener, E. G., & Squire, L. R. (2003). Recognition memory and the human hippocampus. *Neuron*, *37*, 171–180.
- Manns, J. R., & Squire, L. R. (1999). Impaired recognition memory on the Doors and People test after damage limited to the hippocampal region. *Hippocampus*, *9*, 495–499.
- Mayes, A. R., Holdstock, J. S., Isaac, C. L., Hunkin, N. M., & Roberts, N. (2002). Relative sparing of item recognition memory in a patient with adult-onset damage limited to the hippocampus. *Hippocampus*, *12*, 325–340.
- Mayes, A. R., Holdstock, J. S., Isaac, C. L., Montaldi, D., Grigor, J., Gummer, A. et al. (2004). Associative recognition in a patient with selective hippocampal lesions and relatively normal item recognition. *Hippocampus*, *14*, 763–784.
- Mayes, A. R., Isaac, C. L., Downes, J. J., Holdstock, J. S., Hunkin, N. M., Montaldi, D. et al. (2001). Memory for single items, word pairs, and temporal order in a patient with selective hippocampal lesions. *Cognitive Neuropsychology*, *18*, 97–123.
- Mayes, A. R., Isaac, C. L., Holdstock, J. S., Cariga, P., Gummer, A., & Roberts, N. (2003). Long-term amnesia: A review and detailed illustrative case study. *Cortex*, *39*, 567–603.
- Meunier, M., Bachevalier, J., Mishkin, M., & Murray, E. A. (1993). Effects on visual recognition of combined and separate ablations of the entorhinal and perirhinal cortex in rhesus monkeys. *Journal of Neuroscience*, *12*, 5418–5432.

- Meunier, M., Hadfield, J., Bachevalier, J., & Murray, E. A. (1996). Effects of rhinal cortex lesions combined with hippocampectomy on visual recognition memory in rhesus monkeys. *Journal of Neurophysiology*, *75*, 1190–1205.
- Murray, E. A., & Bussey, T. J. (1999). Perceptual-mnemonic functions of the perirhinal cortex. *Trends in Cognitive Sciences*, *3*, 142–151.
- Murray, E. A., Graham, K. S., & Gaffan, D. (this issue). Perirhinal cortex and its neighbours in the medial temporal lobe: Contributions to memory and perception. *Quarterly Journal of Experimental Psychology*, *58B*, 378–396.
- Murray, E. A., & Mishkin, M. (1985). Amygdalectomy impairs crossmodal association in monkeys. *Science*, *228*, 604–606.
- Murray, E. A., & Mishkin, M. (1986). Visual recognition in monkeys following rhinal cortical ablations combined with either amygdalectomy or hippocampectomy. *Journal of Neuroscience*, *7*, 1991–2003.
- Murray, E. A., & Mishkin, M. (1996). 40-Minute visual recognition memory in rhesus monkeys with hippocampal lesions. *Society for Neuroscience Abstracts*, *116.9*.
- Norman, K. A., & O'Reilly, R. C. (2001). *Modelling hippocampal and neocortical contributions to recognition memory: A complementary learning systems approach* (ICS Tech. Rep. No. 01-02). Boulder, CO: University of Colorado, Institute of Cognitive Science.
- O'Reilly, R. C., & Norman, K. A. (2002). Hippocampal and neocortical contributions to memory: Advances in the complementary learning systems framework. *Trends in Cognitive Sciences*, *6*, 505–510.
- Ramus, S. J., Zola-Morgan, S., & Squire, L. R. (1994). Effects of lesions of perirhinal cortex or parahippocampal cortex on memory in monkeys. *Society for Neuroscience Abstracts*, *20*, 1074.
- Reed, J. M., & Squire, L. R. (1997). Impaired recognition memory in patients with lesions limited to the hippocampal formation. *Behavioral Neuroscience*, *111*, 667–675.
- Rothblat, L. A., & Kromer, L. F. (1991). Object recognition memory in the rat: The role of the hippocampus. *Behavioural Brain Research*, *42*, 25–32.
- Shaw, C., & Aggleton, J. P. (1993). The effects of fornix and medial prefrontal lesions on delayed non-matching-to-sample by rats. *Behavioural Brain Research*, *54*, 91–102.
- Shaw, C., Kentridge, R. W., & Aggleton, J. P. (1990). Cross-modal matching by amnesic patients. *Neuropsychologia*, *28*, 665–671.
- Squire, L. R., & Zola-Morgan, S. (1991). The medial temporal-lobe memory system. *Science*, *253*, 1380–1386.
- Stark, C. E. L., & Squire, L. R. (2000). Intact visual perceptual discrimination in humans in the absence of perirhinal cortex. *Learning and Memory*, *7*, 273–278.
- Vargha-Khadem, F., Gadian, D. G., Watkins, K. E., Connelly, A., van Paesschen, W., & Mishkin, M. (1997). Differential effects of early hippocampal pathology on episodic and semantic memory. *Science*, *277*, 376–380.
- Yonelinas, A. P. (2002). The nature of recollection and familiarity: A review of 30 years of research. *Journal of Memory and Language*, *46*, 441–517.
- Zola-Morgan, S., & Squire, L. R. (1986). Memory impairment in monkeys following lesions limited to the hippocampus. *Behavioural Neuroscience*, *100*, 155–160.
- Zola-Morgan, S., Squire, L. R., & Amaral, D. G. (1989). Lesions of the hippocampal formation but not lesions of the fornix or the mammillary nuclei produce long-lasting memory impairment in monkeys. *Journal of Neuroscience*, *100*, 155–160.
- Zola-Morgan, S., Squire, L. R., Clower, R. P., & Rempel, N. L. (1993). Damage to the perirhinal cortex exacerbates memory impairment following lesions to the hippocampal formation. *Journal of Neuroscience*, *13*, 251–265.